

Effects of erythromycin on milk yield, rumen contraction rate and blood beta-hydroxybutyrate concentration in dairy cows after laparoscopic reposition of the left displaced abomasum

M. FREICK¹, J. WEBER¹, O. PASSARGE¹, S.D. KEVORK²

¹Veterinary Practice Zettlitz, Zettlitz OT Methau, Germany

²Statistical Consulting Unit StaBLaB, Munich, Germany

ABSTRACT: The objective of this study was to evaluate the beneficial effects of erythromycin (Emy), a prokinetic drug active at the level of the abomasum, duodenum and proximal duodenum, in dairy cows undergoing a laparoscopic repositioning of left abomasal displacement (LAD). A total of 71 German Holstein cows were randomly assigned into three groups. Cows of the group Emy1 received erythromycin once preoperatively (10 mg/kg; intramuscularly). Animals of the group Emy3 were additionally treated twice after surgery at intervals of 24 h each (10 mg/kg; intramuscularly), while cows in the control group did not receive erythromycin. The milk yield of the patients was documented on Days 0, 1, 2, 3, 6 and 10 and the rumen contraction rate (RCR) was determined on Days 1 and 3. Additionally, the measurement of the concentration of beta-hydroxybutyrate (BHB) in whole blood samples was performed on Days 0, 1 and 3. Significant differences between the study groups regarding the cure rates, milk yield (in relation to Day 0); BHB concentrations and RCR could not be determined on the observation dates. With respect to a prudent use of antibiotics in livestock, the application of erythromycin as a prokinetic drug cannot be recommended for the present in cows undergoing a laparoscopic correction of LAD.

Keywords: cattle; dislocatio abomasi; endoscopy; prokinetic drugs; gastrointestinal mobility

List of abbreviations

BHB = beta-hydroxybutyrate; **DIM** = days in milk; **Emy** = erythromycin; **GIT** = gastro-intestinal tract; **LAD** = left abomasal displacement; **NSAID** = non-steroidal anti-inflammatory drug; **RCR** = rumen contraction rate

Left abomasal displacement (LAD) is an economically significant disease in high-yielding dairy herds (Staufenbiel 1998; Geishauser et al. 2000; Kotter 2005), whose treatment requires a curative measures (Wittek 2010). Laparoscopic approaches of repositioning of LAD (Janowitz 1998; Barisani 2004; Christiansen 2004) are considered to be minimally invasive, time- and cost-effective as well as safe (Sattler and Wittek 2011).

The abomasal emptying rate is reduced in cows with LAD in the pre- and postoperative period (Wittek et al. 2005). Erythromycin, a motilin receptor agonist (Ungemach 2010), is considered as the most effective prokinetic drug at the abomasum

in both calves (Afshari et al. 2009) and adult cattle (Wittek et al. 2008a; Wittek et al. 2008b; Wittek 2010; Constable et al. 2012; Sanger et al. 2013). Its suitability for the treatment of postoperative abomasal hypomotility after surgical correction of LAD or abomasal volvulus was shown by Wittek et al. (2008a; Wittek et al. 2008b). A single dose of erythromycin administered preoperatively had positive effects on abomasal emptying rate, rumen contraction rate (RCR) and milk yield after reposition of LAD by laparotomy and omentopexy in the immediate postoperative period (Wittek et al. 2008a). Erythromycin is a member of the macrolide antibiotic family (Kroker 2010). Currently, public

interest in a restricted use of antibiotics is on the increase (Swinkels et al. 2015) – not least due to the detection of antibiotic-resistant bacterial strains in human and veterinary medicine (Thabit et al. 2015), as well as the risk of antibiotic residues in food (Virolainen and Karp 2014).

Until now, data on beneficial effects of an erythromycin administration before or after laparoscopic repositioning of LAD are lacking. Therefore, this field study was conducted to investigate whether a single or triple erythromycin application has positive effects on outcome variables which can be determined easily at cow-side, i.e. milk yield, RCR and beta-hydroxybutyrate (BHB) blood concentrations, in the postoperative period in cows undergoing a laparoscopic abomasopexy. The hypothesis was that postoperative abomasal motility can be improved by parenteral erythromycin application and, as a consequence of a higher feed intake, milk yield and RCR may increase and the BHB concentrations might reach physiological values at a faster rate.

MATERIAL AND METHODS

Study design and animals. This study was designed as a randomised, controlled and partially blinded clinical trial (stockmen, milkers). The herd veterinarian and the statistician were not blinded. All procedures were performed as part of routine diagnostic and therapeutic procedures within the farm with informed owner consent.

Sample size was calculated using a web-based calculator (available at: <http://imsiweb.uni-koeln.de/beratung/rechner/b2.html>). On the basis of the mean milk yield of cows one day after repositioning of LAD (mean \pm standard deviation: 13 ± 4 kg) known from historical herd data, the effect size was planned. A sample size of at least 16 animals in each group was necessary to allow a difference of 4 kg (increase from 13 to 17 kg) to be detected at Day 1 after surgery with a statistical power of 0.8 and $\alpha = 0.05$.

Cows of the German Black Pied Holstein breed from a German dairy farm (mean herd size 1850 cows; mean herd performance 9800 kg/lactation; cubicle housing and total mixed ration feeding) were enrolled in this study if a LAD was diagnosed (Dirksen 1990) within the observation period (2013–2014). A routine physical examination was performed (rectal temperature, respiratory rate

and heart rate). As a further prerequisite for enrolment in this trial cows must have been in milk for seven to 50 days (DIM). Cows with signs of systemic illness (e.g. rectal temperature > 39.5 °C, clinical mastitis, watery diarrhoea or evidence of peritonitis during surgery) were excluded from the study as proposed by Wittek et al. (2008a).

Treatment groups. Animals were randomised on the basis of the final numeral of the ear tag number (FNET). A single dose of erythromycin (10 mg/kg; Erythrocin vet. 200 mg/ml, CEVA Tiergesundheit GmbH, Duesseldorf, Germany) was injected intramuscularly to cows of the Emy1 group (FNET 0–2) one hour prior to surgery. In cows of the Emy3 group (FNET 3–5) erythromycin was administered additionally 24 and 48 h after the laparoscopic correction using the same dosage as in the Emy1 group. Cows belonging to the control group (Co; FNET 6–9) did not receive any specific treatment to prevent postoperative hypomotility of the gastrointestinal tract (GIT). Injections were performed at the medium third of the neck. LAD was corrected by abomasopexy using the laparoscopic approach according to Christiansen (2004).

Additionally, all animals in the study were given a standard therapy consisting of a glucose/fructose solution (Invert 40%, 500 ml *i.v.*, single dose; Selectavet Dr. Otto Fischer GmbH, Weyarn-Holzolling, Germany), antibiosis (procaine benzylpenicillin, 30 000 IU/kg *i.m.*, three times at intervals of 24 h; Procain-Penicillin-Suspension 300 mg/ml, Albrecht GmbH, Aulendorf, Germany) as well as an antiphlogistic treatment (metamizole, 30 mg/kg *i.v.*, three times at intervals of 24 h; Metapyrin 500 mg/ml, Serumwerk Bernburg AG, Bernburg/Germany) and the application of glucocorticoids (dexamethasone-sodium phosphate, 0.02 mg/kg *i.v.*, single dose; Dexamethason 4 mg/ml, Vetoquinol GmbH, Ravensburg, Germany).

Data collection. On the day of surgery, individual cow data (lactation number, DIM, concomitant disorders, milk yield one week before surgery) were taken from the herd management software (HERDE[®] dsp-Agrosoft GmbH, Ketzin, Germany). The milk yield of the patients was documented on the day of surgery (Day 0; corresponds to the date of diagnosis) as well as on Days 1, 2, 3, 6 and 10 and the RCR (n/3 min) was determined on Days 1 and 3 (morning measurement). Furthermore, the measurement of the BHB concentration (FreeStyle Precision, Abbott GmbH & Co. KG, Wiesbaden,

doi: 10.17221/20/2016-VETMED

Germany; Iwersen et al. 2013) in freshly collected whole blood samples obtained from the coccygeal vein was performed on Days 0, 1 and 3.

The animals were kept in tie-stalls for ten days after surgery. During this period, they received hay *ad libitum* in addition to the total mixed ration. Afterwards, the cows were discharged into cubicle housing in a convalescent group. Cows that left the herd before the 10th day after surgery were used only to calculate the cure rates, but not included in the further evaluation of the outcomes. Thus, only data of animals which had an undisturbed convalescence were analysed.

Statistical analysis. For data collection and treatment a standard software package (Microsoft Office®, Microsoft Corporation, Redmond, USA) was used. Treatment effects at single time points were analysed by an ANCOVA model taking the baseline as a covariate (Vickers and Altman 2001). Furthermore, we used a mixed model to check the difference between the groups in milk yield over time. For taking into account the repeated measure structure, a random cow effect has been included. Statistical analysis was performed using the statistical program R (Wickham 2009; R Core Team 2014).

RESULTS

In total, 26 cows were assigned to group Emy1, 18 animals to group Emy3 and 27 cows to the control group, respectively. Individual characteristics of the animals enrolled in this study are summarised in Table 1. Noticeably, the DIM of the Emy3

Table 1. Selected data of the individual cows enrolled in this study

Parameter	Group	Mean ± SD ¹
Lactation number	Emy1	3.1 ± 1.3 ^a
	Emy3	2.8 ± 1.2 ^a
	Control	2.9 ± 0.8 ^a
Days in milk	Emy1	16.3 ± 7.8 ^{a,b}
	Emy3	17.5 ± 7.2 ^b
	Control	13.1 ± 5.1 ^a
Milk yield 7 days before surgery (kg)	Emy1	25.1 ± 9.1 ^a
	Emy3	26.7 ± 8.3 ^a
	Control	26.9 ± 7.1 ^a

SD = standard deviation

¹different superscripts indicate significant differences between the study groups

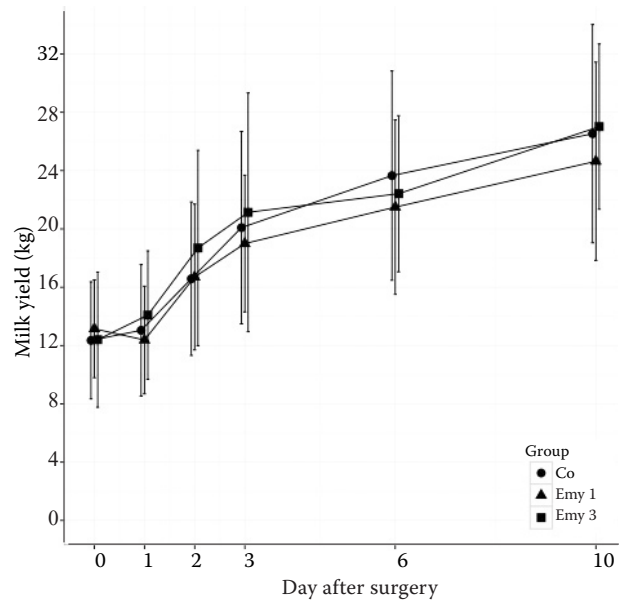


Figure 1. Daily milk yield (kg) in the study groups (0 = day of surgery)

group were significantly higher than in the control group ($P = 0.034$).

At the time of diagnosis of LAD 69.2% (Emy1), 83.3% (Emy3) and 62.9% of the cows (Co), respectively, had a concomitant disease. The proportions did not differ significantly between the study groups. The cure rates, defined as the proportion of patients who were discharged from the convalescent group to their performance group three weeks after surgery, were 96.2% (Emy1), 88.9% (Emy3) and 92.6% (Co), respectively. The differences were not significant.

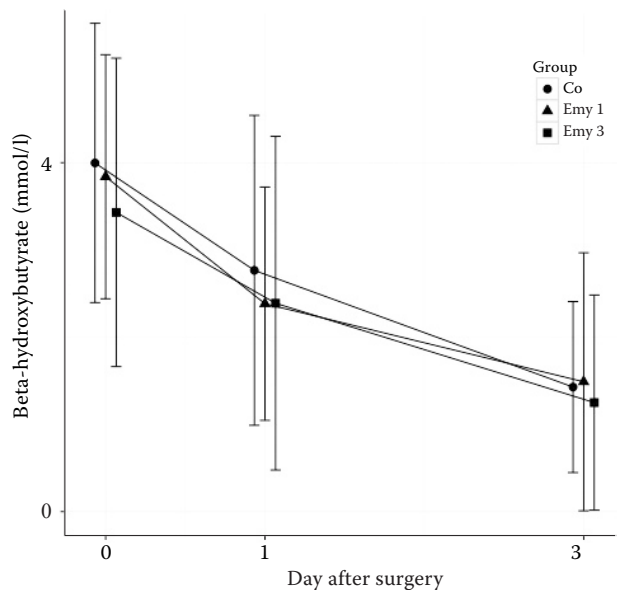


Figure 2. Beta-hydroxybutyrate concentrations in the study groups (0 = day of surgery)

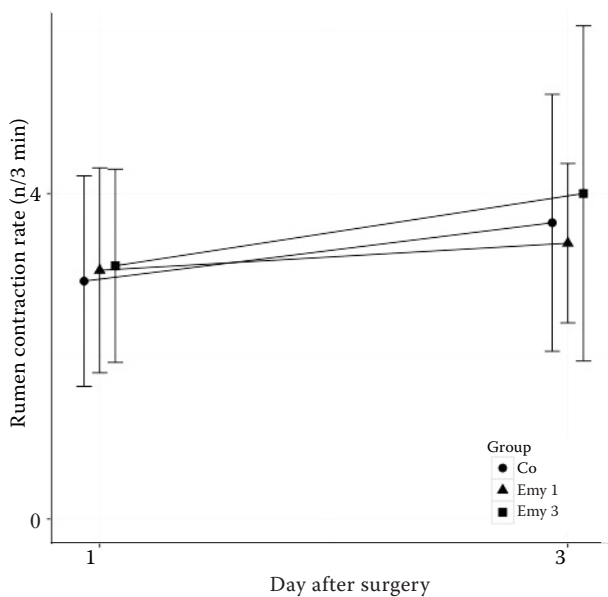


Figure 3. Rumen contraction rates in the study groups

The outcome variables milk yield, RCR and BHB were evaluated in 25 (Emy1), 16 (Emy3) and 25 cows (Co), respectively. For the ANCOVA analysis at single time points, no significant effects were observed (Figure 1–3).

Results of the Mixed Model for the outcome variable milk yield are outlined in Table 2.

DISCUSSION

Abomasal displacements in dairy cows can occur at any time during lactation or in the dry cow period; however, they occur most frequently in early lactation (Loptien et al. 2005; Freick et al. 2013). Thus, the animals included in this study (7–50 DIM) represent typical patients with this disorder. Several surgical procedures for repositioning of LAD have been described (reviewed in Sattler and Wittek 2011), i.e. percutaneous abomasopexy, right flank laparotomy and omentopexy, left flank laparotomy and abomaso- or omentopexy, ventral paramedian abomaso- or omentopexy, and laparoscopic approaches. Latter methods (Janowitz 1998; Barisani 2004; Christiansen 2004) are considered to be minimally invasive and safe methods for practice (Sattler and Wittek 2011). From the literature it is known that cows with LAD have a reduced abomasal emptying rate which further decreases immediately after surgical correction (Wittek et al. 2005). In a study by Wittek et al. (2008a), abomasal emptying rate (D-xylose absorption test,

Table 2. Mixed model results for the variable outcome milk yield. Covariates are milk yield at baseline, treatment group and the time (number of days) as a categorical variable

	Sum Sq	Mean Sq	DF	F-value	P-value
Baseline	296.6	296.56	1	63	< 0.001
Group	40.5	20.24	2	63	0.2104
Days	5574.3	1858.09	4	192	< 0.001
Group × days	76.8	12.79	8	192	0.4200

DF = degrees of freedom; Mean Sq = mean squared error; Sum Sq = sum of squares

pharmacokinetic T_{max} model; group Emy vs control group: $T_{max} = 164 \pm 64$ min vs $T_{max} = 276 \pm 72$ min, $P < 0.001$), relative milk yield (baseline level at Day 0: group Emy vs control group: 7.5 ± 3.2 kg vs 8.9 ± 4.5 kg, $P > 0.05$; Day 1: 175 vs 125% of Day 0, $P < 0.001$; Day 2: 170 vs 125% of Day 0, $P < 0.001$) and RCR (group Emy vs control group, Day 1: 3.1 vs 1.9 contractions per 3 min) were increased significantly after reposition of LAD using laparotomy and omentopexy by a preoperative erythromycin administration using the same dosage as in our study. Therefore, in the present field trial we investigated whether positive effects on clinically easily measurable parameters (milk yield, BHB, RCR) after laparoscopic abomasopexy can be achieved with an erythromycin treatment. Since the duration of postoperative abomasal hypomotility is unknown (Wittek et al. 2005), erythromycin was applied three times at intervals of 24 h in the Emy3 study group. In human medicine, low doses of this drug are administered repeatedly to increase gastric emptying in patients with gastroparesis and, thus, to facilitate a sustained clinical benefit (Dhir and Richter 2004).

Clinical and subclinical ketosis are associated with a negative energy balance in the postpartum period leading to lipomobilisation and excessive production of ketone bodies in the liver and are risk factors for other disorders such as metritis, mastitis and displaced abomasum (Suthar et al. 2013). Thus, elevated BHB levels are commonly found in cows with LAD prior to surgery (Wittek et al. 2008a; Suthar et al. 2013). After repositioning of the displaced abomasum, BHB values decreased in all treatment groups in the postoperative period likely due to an increased feed intake and energy supply, which was also observed by Newby et al. (2013) in cows undergoing a right flank laparotomy

doi: 10.17221/20/2016-VETMED

or a paramedian approach to correct LAD. All cows in this study received a glucose/fructose infusion (containing 220 g glucose-monohydrate and 200 g fructose) at the time of surgery to improve energy supply; the total amount of the administered glucose was below the maintenance requirements of lactating dairy cows. Presumably, dexamethasone treatment contributed to the rapid decrease of BHB until Day 3 after surgery since it affects glucose and lipid metabolism in early lactating dairy cows (Kusenda et al. 2013). However, erythromycin had no additional beneficial effect on BHB values or milk yield beyond this standard therapy.

The cows of the three study groups differed significantly in their DIM values. Therefore, not only the absolute values of the outcome variables were compared, but in the case of milk yield and BHB additionally their changes in relation to the day of surgery. Neither the milk yield nor the RCR, nor the concentrations of BHB were influenced significantly by a single or triple erythromycin application compared to the untreated control in cows with an uncomplicated recovery phase. This may be explained by the less pronounced abomasal hypomotility after laparoscopic abomasal repositioning compared to laparotomy and omentopexy. In a study conducted by Wittek et al. (2009), abomasal emptying in the laparoscopy group was significantly faster than in the group of cows with laparotomy (D-xylose absorption test, T_{\max} model: 192 ± 51 min vs 264 ± 94 min). In contrast, maximum concentrations of D-xylose in the serum of healthy cows in early lactation were measured already after 108 ± 14 min (Wittek et al. 2005). Since erythromycin is not able to rescue the LAD-associated abomasal hypomotility completely (Wittek et al. 2008a), in the present study its effect was possibly not sufficient to achieve clinically measurable benefits. This hypothesis should be verified by further investigations using absorption tests and ultrasonography to measure the abomasal emptying rate after laparoscopic abomasopexy with and without the use of prokinetics.

A further explanation for the non-measurable effect of erythromycin on the investigated parameters is the use of the non-steroidal anti-inflammatory drug (NSAID) metamizole in all animals in this field study for postoperative pain management. Pain and inflammation may be a cause for postoperative gastrointestinal hypomotility (Steinbrook 1998; Schwarz et al. 2001). In the study of Wittek

et al. (2008a), administration of the NSAID flunixin meglumine resulted in a significant increase of the RCR on Day 1 after surgery, but did not alter the abomasal emptying. In another study the postoperative milk yield, feed intake, rumination activity and faecal consistency were affected positively by the same active ingredient (Guglielmini 2001). Otherwise, in a study by Newby et al. (2013) a label dose of ketoprofen administered to cows immediately after surgical correction of LAD (right flank laparotomy or paramedian approach) and 24 h postoperatively did not alter the heart rate, respiration rate, rumen motility, BHB levels and behavioural outcomes. These varying effects underline the fact that the effectiveness of NSAIDs for treating postoperative hypomotility of the GIT depends on agent and species (discussed in Wittek et al. 2008a). Metamizole has an analgesic and spasmolytic effect on the smooth muscle of the GIT (Loscher 2010). Due to the pronounced visceral analgesia, metamizole could have reduced the severity of the postoperative gastrointestinal hypomotility (Pairet and Ruckebusch 1989), and, thus, clinically measurable effects of erythromycin were absent.

Wittek et al. (2012) compared different techniques (right flank laparotomy and omentopexy, left flank laparotomy and omentopexy, and laparoscopic abomasopexy) with respect to the systemic and peritoneal inflammatory response. In none of the groups were bacteria present in peritoneal fluid after surgery. Peritoneal fluid leukocytes increased in all groups with the highest value after laparoscopy, probably as only laparoscopic abomasopexy required perforation of the abomasal wall. Creatine kinase increased after laparotomy in both blood and peritoneal fluid, but in peritoneal fluid only after laparoscopy, indicating a less pronounced muscular damage (Wittek et al. 2012) and, thus, possibly less pain. Differences in tissue damage and local and/or systemic inflammatory response after repositioning of the displaced abomasum by laparotomy and omentopexy or laparoscopy can be reasons for different severities of postoperative abomasal hypomotility and, thus, may influence the effects of an erythromycin application.

Wittek et al. (2008a) and Wittek et al. (2009) performed their studies in a university hospital, whereas the present trial was undertaken on a commercial dairy farm. Thus, it can be supposed that the time between the onset of the abomasal displacement and the surgical intervention was

shorter in our study presumably resulting in a less severe postoperative paralytic ileus. For this reason the use of erythromycin may have been less advantageous.

In comparison to LAD, cases of right displaced abomasum without or with abomasal volvulus occur less frequently (Dirksen 1990; Freick et al. 2013). The application of laparoscopy in this disorder is limited to cows without or with less pronounced volvulus. Thus, as a safe therapy only a right flank laparotomy and omentopexy is recommended (Sattler and Wittek 2011). Characteristics of haemostatic dysfunction and cell damage are evident in cows with abomasal volvulus, e.g. increased L-lactate, D-dimer and lactate dehydrogenase levels as well as necrotic or apoptotic peritoneal neutrophil granulocytes (Grosche et al. 2012). However, immediately after repositioning of the abomasal displacement in cows suffering LAD or abomasal volvulus by right flank laparotomy and omentopexy, there is no difference in abomasal emptying rate (Wittek et al. 2005). A preoperative injection of erythromycin was shown as an effective method for ameliorating postoperative abomasal hypomotility in cows with abomasal volvulus after correction by laparotomy and omentopexy (Wittek et al. 2008b). Currently, no data on the effects of erythromycin after laparoscopic repositioning of the right displaced abomasum exist, possibly due to the limitations of the laparoscopic techniques for this condition.

The present study was conducted on only one farm with a relative low sample size. Due to these limitations, the results can only be generalised to a limited extent and should be confirmed in large-scale investigations, preferably with a multicentric study design. However, differences between surgical approaches used for the correction of LAD seem to exist, when considering the clinical relevance of prokinetics. Furthermore, it is still unknown in which individual cases of LAD (including cow-individual factors such as lactation number, DIM, milk yield, comorbidities) prokinetics can be recommended for a pre- or postoperative application. Likewise, studies in cows that already show symptoms of a postoperative paralytic ileus after correction of abomasal displacement, e.g. lack of feed intake, rumination, and defecation, an increase of abdominal circumference and a progressive deterioration of the general condition (Dirksen 2006) are missing. Thus, further investigations are necessary to inform the specific use of prokinetic drugs in bovine species.

CONCLUSIONS

The results of this study indicate that positive effects on postoperative milk yield, BHB values and RCR after the use of erythromycin as a prokinetic drug following laparoscopic replacement of LAD in cows with a normal convalescent period may not be observed. Further studies are warranted, involving a broader range of clinical-chemical parameters which are commonly altered in cases of LAD (Wittek et al. 2008a; Klevenhusen et al. 2015) or are associated with survival in the herd after surgical correction of LAD (Reynen et al. 2015) (e.g. glucose, non-esterified fatty acids, bilirubin, aspartate aminotransferase, glutamate dehydrogenase, serum amyloid A, serum calcium, serum magnesium, serum chloride, parameters of acid-base balance, insulin sensitivity), an assessment of cow attitude and appetite (Newby et al. 2013), and the measurement of the abomasal emptying rate (Wittek et al. 2008a).

Acknowledgement

The authors thank the executive board of the dairy farm for giving us the opportunity to realise this study and for funding. Special thanks go to the staff of the farm (especially Ilona Sieber and Andrea Endtmann) for expert technical assistance. We are grateful that Prof. Dr. Helmut Kuchenhoff (Munich, Germany) reviewed the manuscript critically.

REFERENCES

- Afshari GR, Nouri M, Hassan EB, Mokhber-Dezfooli MR, Constable PD (2009): Effect of parenteral administration of ivermectin and erythromycin on abomasal emptying rate in suckling calves. *American Journal of Veterinary Research* 70, 527–531.
- Barisani C (2004): Advancement of the Janowitz technique for replacement of the left displaced abomasum by Barisani (in Italian). *Summa* 15, 35–39.
- Christiansen K (2004): Laparoscopic operation for left displaced abomasum (Janowitz operation) for ruminants in a standing position (in German). *Tierärztliche Praxis G* 32, 118–121.
- Constable PD, Nouri M, Sen I, Baird AN, Wittek T (2012): Evidence-based use of prokinetic drugs for abomasal disorders in cattle. *Veterinary Clinics of North America Food Animal Practice* 28, 51–70.

doi: 10.17221/20/2016-VETMED

- Dhir R, Richter JE (2004): Erythromycin in the short- and long-term control of dyspepsia symptoms in patients with gastroparesis. *Journal of Clinical Gastroenterology* 38, 237–242.
- Dirksen G (1990): Digestive system. In: Rosenberger G (ed.): *The Clinical Examination in Cattle* (in German). 3rd edn. Parey, Hamburg, Germany. 288–400.
- Dirksen G (2006): Ileus in cattle. In: Rosenberger G (ed.): *The Clinical Examination in Cattle* (in German). 3rd edn. Parey, Hamburg, Germany. 514–517.
- Freick M, Sieber I, Endtmann A, Passarge U, Passarge O (2013): Laparoscopic reposition of the displaced abomasum in a dairy herd in Saxony/Germany – a case series (in German). *Tierärztliche Umschau* 68, 311–321.
- Geishauser T, Leslie K, Duffield T (2000): Metabolic aspects in the etiology of displaced abomasum. *Veterinary Clinics of North America Food Animal Practice* 16, 255–265.
- Grosche A, Furl M, Wittek T (2012): Peritoneal fluid analysis in dairy cows with left displaced abomasum and abomasal volvulus. *Veterinary Record* 170, 413.
- Guglielmini C (2001): Use of flunixin meglumine in cattle with left abomasal displacement (in Italian). *Atti della Società Italiana Buiatria* 33, 269–273.
- Iwersen M, Klein-Jobstl D, Pichler M, Roland L, Fidschuster B, Schwendenwein I, Drillich M (2013): Comparison of 2 electronic cowside tests to detect subclinical ketosis in dairy cows and the influence of the temperature and type of blood sample on the test results. *Journal of Dairy Science* 96, 7719–7730.
- Janowitz H (1998): Laparoscopic reposition and fixation of the left displaced abomasum in cattle (in German). *Tierärztliche Praxis G* 26, 308–313.
- Klevenhusen F, Humer E, Metzler-Zebeli B, Podstatzky-Lichtenstein L, Wittek T, Zebeli Q (2015): Metabolic profile and inflammatory responses in dairy cows with left displaced abomasum kept under small-scaled farm conditions. *Animals (Basel)* 5, 1021–1033.
- Kotter R (2005): Treatment of cows with left abomasal displacement by laparoscopic abomasopexy according to Janowitz – a field study (in German). [Doctoral Thesis.] University of Veterinary Medicine Hannover, Foundation, Germany.
- Kroker R (2010): Pharmaceuticals for treatment and prevention of bacterial infections (in German). In: Loscher W, Ungemach FR, Kroker R (eds): *Pharmacotherapy in Companion Animals and Livestock* (in German). 8th edn. Enke, Stuttgart, Germany. 249–297.
- Kusenda M, Kaske M, Piechotta M, Locher L, Starke A, Huber K, Rehage J (2013): Effects of dexamethasone-21-isonicotinate on peripheral insulin action in dairy cows 5 days after surgical correction of abomasal displacement. *Journal of Veterinary Internal Medicine* 27, 200–206.
- Loptien A, Loschner U, Staufenbiel R (2005): Cross-sectional study of occurrence and treatment success of abomasum displacement with respect to surgical approach (in German). *Tierärztliche Praxis G* 33, 419–426.
- Loscher W (2010): Pharmaceuticals with effects in the central nervous system. In: Loscher W, Ungemach FR, Kroker R (eds): *Pharmacotherapy in Companion Animals and Livestock* (in German). 8th edn. Enke, Stuttgart, Germany. 64–133.
- Newby NC, Pearl DL, LeBlanc SJ, Leslie KE, von Keyserlingk MA, Duffield TF (2013): The effect of administering ketoprofen on the physiology and behavior of dairy cows following surgery to correct a left displaced abomasum. *Journal of Dairy Science* 96, 1511–1520.
- Pairet M, Ruckebusch Y (1989): On the relevance of non-steroidal anti-inflammatory drugs in the prevention of paralytic ileus in rodents. *Journal of Pharmacy and Pharmacology* 41, 757–761.
- R Core Team (2014): *R: A language and environment for statistical computing*. R Foundation for Statistical Computing, Vienna, Austria, 2014. Available: URL <http://www.R-project.org/> (Accessed 1 November 2015).
- Reynen JL, Kelton DF, LeBlanc SJ, Newby NC, Duffield TF (2015): Factors associated with survival in the herd for dairy cows following surgery to correct left displaced abomasum. *Journal of Dairy Science* 98, 3806–3813.
- Sanger GJ, Wang Y, Hobson A, Broad J (2013): Motilin: towards a new understanding of the gastrointestinal neuropharmacology and therapeutic use of motilin receptor agonists. *British Journal of Pharmacology* 170, 1323–1332.
- Sattler T, Wittek T (2011): Reposition of displaced abomasum – an overview (in German). *Praktischer Tierarzt* 92, 900–910.
- Schwarz NT, Kalff JC, Turler A, Engel BM, Watkins SC, Billiar TR, Bauer AJ (2001): Prostanoid production via COX-2 as causative mechanisms of rodent postoperative ileus. *Gastroenterology* 121, 1354–1371.
- Staufenbiel R (1998): Approaches to prevent abomasal displacement. In: Furl M (ed.): *Etiology, Pathogenesis, Diagnostics, Prognosis, Therapy and Prevention of Abomasal Displacement* (in German). Proceedings of the International Workshop, Leipzig, Germany. 291–309.
- Steinbrook RA (1998): Epidural anesthesia and gastrointestinal motility. *Anesthesia and Analgesia* 86, 837–844.
- Suthar VS, Canelas-Raposo J, Deniz A, Heuwieser W (2013): Prevalence of subclinical ketosis and relationships with postpartum diseases in European dairy cows. *Journal of Dairy Science* 96, 2925–2938.

- Swinkels JM, Hilkens A, Zoche-Golob V, Kromker V, Budiger M, Jansen J, Lam TJ (2015): Social influences on the duration of antibiotic treatment of clinical mastitis in dairy cows. *Journal of Dairy Science* 98, 2369–2380.
- Thabit AK, Crandon JL, Nicolau DP (2015): Antimicrobial resistance: impact on clinical and economic outcomes and the need for new antimicrobials. *Expert Opinion on Pharmacotherapy* 16, 159–177.
- Ungemach FR (2010): Pharmaceuticals with effects in the gastrointestinal tract. In: Loscher W, Ungemach FR, Kroker R (eds): *Pharmacotherapy in Companion Animals and Livestock* (in German). 8th edn. Enke, Stuttgart, Germany. 217–243.
- Vickers AJ, Altman DG (2001): Analysing controlled trials with baseline and follow up measurements. *British Medical Journal* 323, 1123–1124.
- Virolainen N, Karp M (2014): Biosensors, antibiotics and food. *Advances in Biochemical Engineering/Biotechnology* 145, 153–185.
- Wickham H (ed.) (2009): *ggplot2: Elegant Graphics for Data Analysis*. Springer, New York, USA. 213 pp.
- Wittek T (2010): A review on stimulation of abomasal motility and emptying after surgical correction of left displaced abomasum or abomasal volvulus (in German). *Praktischer Tierarzt* 91, 892–898.
- Wittek T, Schreiber K, Furl M, Constable PD (2005): Use of the D-xylose absorption test to measure abomasal emptying rate in healthy lactating Holstein-Friesian cows and in cows with left displaced abomasum or abomasal volvulus. *Journal of Veterinary Internal Medicine* 19, 905–913.
- Wittek T, Tischer K, Gieseler T, Furl M, Constable PD (2008a): Effect of preoperative administration of erythromycin or flunixin meglumine on postoperative abomasal emptying rate in dairy cows undergoing surgical correction of left displacement of the abomasum. *Journal of the American Veterinary Medical Association* 232, 418–423.
- Wittek T, Tischer K, Korner I, Sattler T, Constable PD, Furl M (2008b): Effect of preoperative erythromycin or dexamethasone/vitamin C on postoperative abomasal emptying rate in dairy cows undergoing surgical correction of abomasal volvulus. *Veterinary Surgery* 37, 537–544.
- Wittek T, Locher LE, Alkaassem A, Constable PD (2009): Effect of surgical correction of left displaced abomasum by means of omentopexy via right flank laparotomy or two-step laparoscopy-guided abomasopexy on postoperative abomasal emptying rate in lactating dairy cows. *Journal of the American Veterinary Medical Association* 234, 652–657.
- Wittek T, Furl M, Grosche A (2012): Peritoneal inflammatory response to surgical correction of left displaced abomasum using different techniques. *Veterinary Record* 171, 594.

Received: 2016–01–31

Accepted after corrections: 2016–07–05

Corresponding Author:

Markus Freick, Veterinary Practice Zettlitz, Strasse der Jugend 68, 09306 Zettlitz OT Methau, Germany
E-mail: mfreick@gmx.de
